

Fingertip Reconstruction with Subcutaneous Island Flap and Composite Graft: A Case Report

Jinha Park, Jin Soo Kim, Sung Hoon Koh, Dong Chul Lee, Si Young Roh, Kyung Jin Lee, Min Ki Hong

Department of Plastic and Reconstructive Surgery, Gwangmyeong Sungae Hospital, Gwangmyeong, Korea

Reconstruction of amputated fingertips is extremely challenging when the amputee is very small and severely crushed. Moreover, there are not many options if distal phalanx is exposed due to defects of soft tissue. We report a case of successful fingertip reconstruction in a 10-month-old girl using a subcutaneous island flap with a composite graft. Her fingertip of the right little finger was amputated stuck by the air purifier. Some soft tissue was lost from the stump and the bone was exposed. There was a very small amputee, and soft tissue was extremely little inside. Replantation was not possible because of the soft tissue defect. The composite graft was inadequate due to the exposure of distal phalanx and defect of soft tissue. Soft tissue island flap based terminal branch of the digital artery was transposed to cover the distal phalanx. After then, the amputee was grafted over the flap. After debridement, most of the soft tissue survived and 0.2x0.2 cm of skin defect was found, which was healed through secondary intention.

Keywords: Island flap, Fingertip, Reconstruction

INTRODUCTION

Reconstruction of amputated fingertips for the infant is extremely challenging when the amputee is very small and severely crushed [1]. Replantation or composite graft is inadequate when there are defects of soft tissue. Stump revision or free flap can be another option, but it is not easy to guarantee the success of free flap in infants due to the small caliber of the vessel [2]. Composite grafting of amputee may be an alternative option [3], but it does not promise the survival of the graft. In addition, the composite graft cannot survive if bones are exposed due to additional soft tissue defect. However, until now, there has been no reported case of performing composite graft simultaneously with subcutaneous island flap. Herein, we report a successful case of fingertip reconstruction with subcutaneous island flap and composite graft.



Case Report

pISSN 2586-3290 · eISSN 2586-3533
Arch Hand Microsurg 2020;25(4):282-286
<https://doi.org/10.12790/ahm.20.0047>

Received: August 20, 2020
Revised: September 17, 2020
Accepted: September 18, 2020

Corresponding author:

Jin Soo Kim
Department of Plastic and Reconstructive Surgery, Gwangmyeong Sungae Hospital, 36 Digital-ro, Gwangmyeong 14241, Korea
Tel: +82-2-2680-7238
Fax: +82-2-2680-7755
E-mail: hlaze@hanmail.net
ORCID:
<https://orcid.org/0000-0003-3369-2974>

© 2020 by Korean Society for Surgery of the Hand, Korean Society for Microsurgery, and Korean Society for Surgery of the Peripheral Nerve.

© This is an open-access article distributed under the terms of the Creative Commons Attribution Non-Commercial License (<http://creativecommons.org/licenses/by-nc/4.0/>), which permits unrestricted non-commercial use, distribution, and reproduction in any medium, provided the original work is properly cited.

CASE REPORT

A 10-month-old girl presented with amputation of a fingertip in right little finger stuck by an air purifier. Radiographically, fracture was not observed, but distal phalanx was exposed at stump (Fig. 1). The amputee was very small, and very little amount of soft tissue was included. In addition, there was a soft tissue defect between the amputee and the stump, and distal phalanx was exposed. Replantation was not possible because of a small and crushed amputee. It was hard to ensure success of composite graft due to soft tissue defect and bone exposure. To cover the exposed bone, subcutaneous island flap based on distal transverse palmar arch (DTPA), which becomes island flap pattern with comparatively longer pedicle, was elevated. The thickness of the flap was approximately 1 mm on average, and it was raised on the subcutaneous plane. The flap was transposed onto the exposed distal phalanx (Figs. 2, 3). Circulation of the flap was checked by bleeding in the subcutaneous fat. Then, a composite graft was performed over the flap with the amputee (Fig. 4). Due to concerns about the circulation of subcutaneous flap, the composite graft was simply sutured at the wound margin. All surgical procedures were performed under loupe magnification. Debridement was done 4 weeks after the surgery. Most of the soft tissue survived and 0.2×0.2 cm (0.04 cm²) of skin defect was found on the fingertip, which was healed through secondary intention. Afterward, there was no

palpable protruding bone on the fingertip, and the infant was able to do normal activities (Fig. 5). There was no difference in the volume of the distal finger pulp between the operated finger and the contralateral side.

Written informed consent was obtained for publication of this case report and accompanying images.

DISCUSSION

Injuries to the fingertip occur very commonly due to trauma. In the meantime, the amputation of the finger also occurs frequently. Amputation of the fingertip occurs much more frequently than other proximal amputation [4]. Various treatments for fingertip amputation have been introduced. Nonsurgical treatment or direct revision of the stump can be done, but

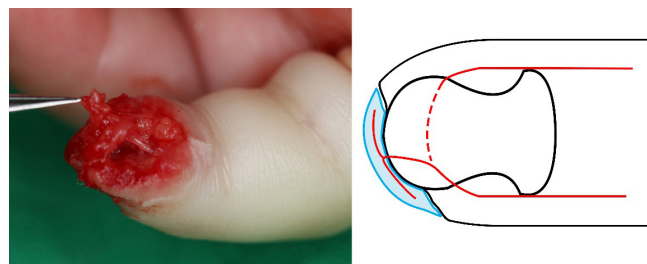


Fig. 2. Subcutaneous island flap based on distal transverse palmar arch was elevated.

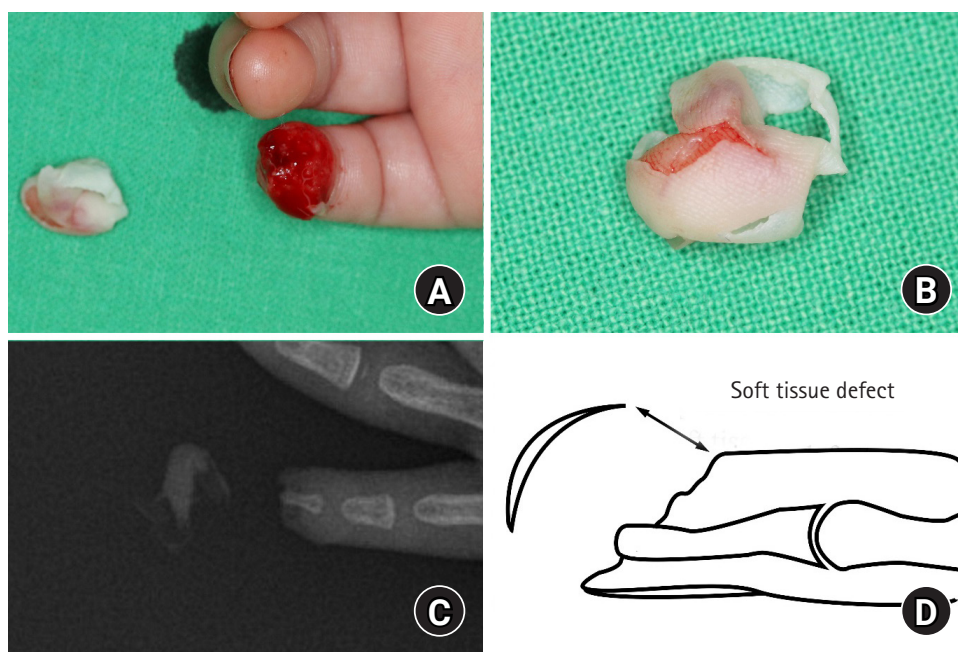


Fig. 1. (A, B) A 10-month-old girl presented with amputation of a fingertip in the right little finger. (C, D) There was loss of soft tissue on the stump with exposed bone.

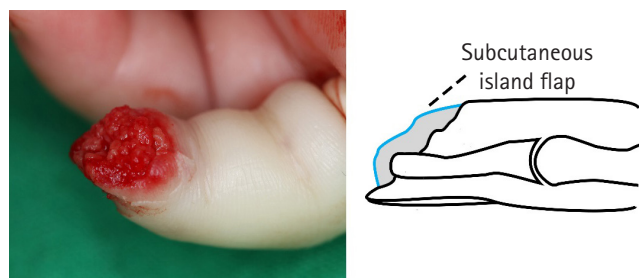


Fig. 3. The flap was transposed to cover exposed distal phalanx.

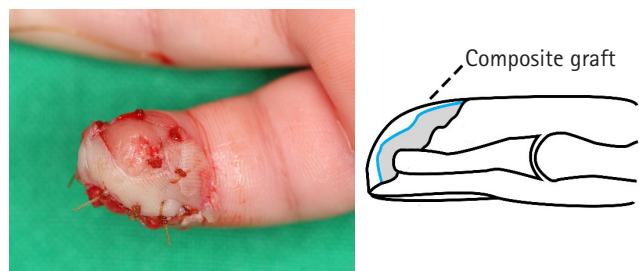


Fig. 4. A composite graft was done over subcutaneous island flap with amputee.

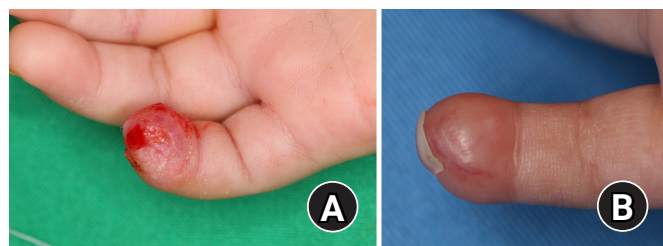


Fig. 5. (A) Minimal skin defect remained after debridement. (B) Three months after debridement, full epithelialization finished.

it causes serious functional and cosmetic problems [5]. The composite graft can be an option. Since the first good results were reported by Douglas [6], it has been widely used in fingertip injuries. However, the engraftment rate of composite graft is low on exposed bone due to the poor vascularity of the bed [7]. Microsurgical replantation can preserve finger length and produce the best results cosmetically or functionally [8]. However, if the amputee is very small and severely crushed, and especially in the case of infant, the small caliber of the vessel makes surgery extremely difficult.

Previous studies revealed that the two palmar digital arteries join at the lunula level and form the DTPA [9]. From the DTPA, central arteries are branched [10]. Considering the characteristics of an arch, it is possible to maintain circulations on both sides when the flap is made by cutting the arch. In the cut arch, artery with comparatively longer pedicle can form a

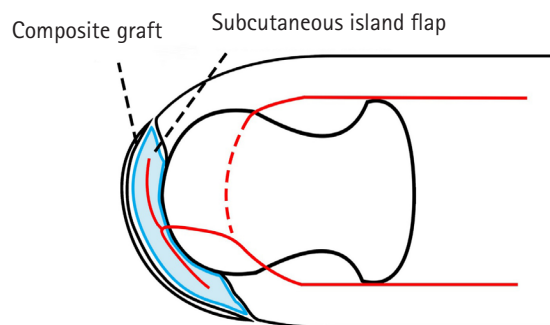


Fig. 6. Schematic diagram of the subcutaneous island flap.

subcutaneous island flap. With careful dissection following the pedicle, U-shaped subcutaneous island flap can be elevated (Fig. 6). Since this subcutaneous island flap does not contain skin, it is impossible to know if the circulation of flaps is maintained through the skin. However, through surgical microscope, it is possible to find whether microbleeding occurs in the fat tissue contained in the subcutaneous island flap. Bleeding from the fat tissue can ensure the circulation of the flap. This subcutaneous island flap can be transposed onto the exposed distal phalanx for coverage. After the flap is sutured over the exposed distal phalanx, the circulation of the flap may decrease due to tension. It could be checked again by microbleeding on the flap. Then, the amputee can be grafted over the subcutaneous island flap as a composite graft. Since the distal portion of the flap will have a relatively lower circulation, partial skin defects can occur on the fingertip. But it can be healed through secondary intention, and larger can be healed through skin grafting.

This subcutaneous island flap is worth considering in that it can prevent bone exposure through internal flaps regardless of whether or not the composite graft is successful. If replantation is difficult and composite graft is not indicated, subcutaneous island flap to cover the bone and doing composite graft over the flap is a possible alternative treatment option.

CONFLICTS OF INTEREST

The authors have nothing to disclose.

REFERENCES

1. Kusuvara H, Ichinohashi K, Sueyoshi Y, Tabata Y, Isogai N. Reconstruction of severely crushed fingertip amputations with basic fibroblast growth factor slow release system. *Plast Reconstr Surg Glob Open*. 2017;5:e1384.
2. Bickel KD, Dosanjh A. Fingertip reconstruction. *J Hand Surg*

- Am. 2008;33:1417-9.
3. Alper N, Sood A, Granick MS. Composite graft repair for distal fingertip amputation. *Eplasty*. 2013;13:ic32.
 4. Venkatramani H, Sabapathy SR. Fingertip replantation: technical considerations and outcome analysis of 24 consecutive fingertip replantations. *Indian J Plast Surg*. 2011;44:237-45.
 5. Wang K, Sears ED, Shauver MJ, Chung KC. A systematic review of outcomes of revision amputation treatment for fingertip amputations. *Hand (N Y)*. 2013;8:139-45.
 6. Douglas B. Successful replacement of completely avulsed portions of fingers as composite grafts. *Plast Reconstr Surg Transplant Bull*. 1959;23:213-25.
 7. Son D, Chu H, Yeo H, Kim J, Han K. Finger tip composite grafting managed with moist-exposed dressing. *J Korean Soc Surg Hand*. 2012;17:9-15.
 8. Ryu DH, Roh SY, Kim JS, Lee DC, Lee KJ. Multiple venous anastomoses decrease the need for intensive postoperative management in tamai zone I replantations. *Arch Plast Surg*. 2018;45:58-61.
 9. Nam YS, Jun YJ, Kim IB, Cho SH, Han HH. Anatomical study of the fingertip artery in Tamai Zone I: clinical significance in fingertip replantation. *J Reconstr Microsurg*. 2017;33:45-8.
 10. Strauch B, de Moura W. Arterial system of the fingers. *J Hand Surg Am*. 1990;15:148-54.

피하 도서형 피판과 복합 조직 이식술을 이용한 수지 첨부의 재건: 증례보고

박진하, 김진수, 고성훈, 이동철, 노시영, 이경진, 홍민기

광명성애병원 성형외과

소아에서 수지 첨부가 절단된 경우 절단부가 작고 혈관이 작아 기술적인 어려움이 있다. 더구나 절단된 수지에서 연부 조직의 결손이 있고 골의 노출이 있는 경우 수술의 방법이 많지 않다. 수지 첨부 절단과 동시에 으깨지면서 결손이 발생한 10개월 여아에게 노출된 원위지골을 피복하기 위하여 피하 도서형 피판과 남아있는 절단부의 피부를 복합 조직 이식술을 이용하여 수술을 시행하였고, 성공적으로 수지 첨부를 재건한 사례에 대해 보고하고자 한다. 환아의 우측 소지의 수지 첨부는 공기청정기에 찍혀 절단된 상태였고, 절단된 수지에는 연부 조직의 결손과 함께 골의 노출이 있었다. 또한 절단부의 크기는 매우 작고, 절단 부위는 압좌되면서 결손이 발생하여 연부 조직은 거의 없는 상태였다. 연부 조직 결손으로 재접합술은 불가능하였으며 원위지골이 노출되어 있고 절단 부위에는 얇은 피부만 남아 있어 복합 조직 이식술은 가능하지 않을 것으로 판단되어 수지동맥의 종말 분지를 혈관경으로 연부 조직 도서형 피판으로 노출된 원위지골을 피복한 후, 피판 위로 절단부의 피부를 이식하였다. 대부분의 연부 조직은 생존하였으며 0.2×0.2 cm 가량의 피부 결손이 발생하였으나 이차 유합 및 구축을 통해 치유되었다.

색인단어: 도서형 피판, 수지 첨부, 재건

접수일 2020년 8월 20일 **수정일** 2020년 9월 17일 **게재확정일** 2020년 9월 18일

교신저자 김진수

14241, 광명시 디지털로 36, 광명성애병원 성형외과

TEL 02-2680-7238 **FAX** 02-2680-7755 **E-mail** hlaze@hanmail.net

ORCID <https://orcid.org/0000-0003-3369-2974>